


# Global Clinical Case Contest 2021-2022

3.  
Place

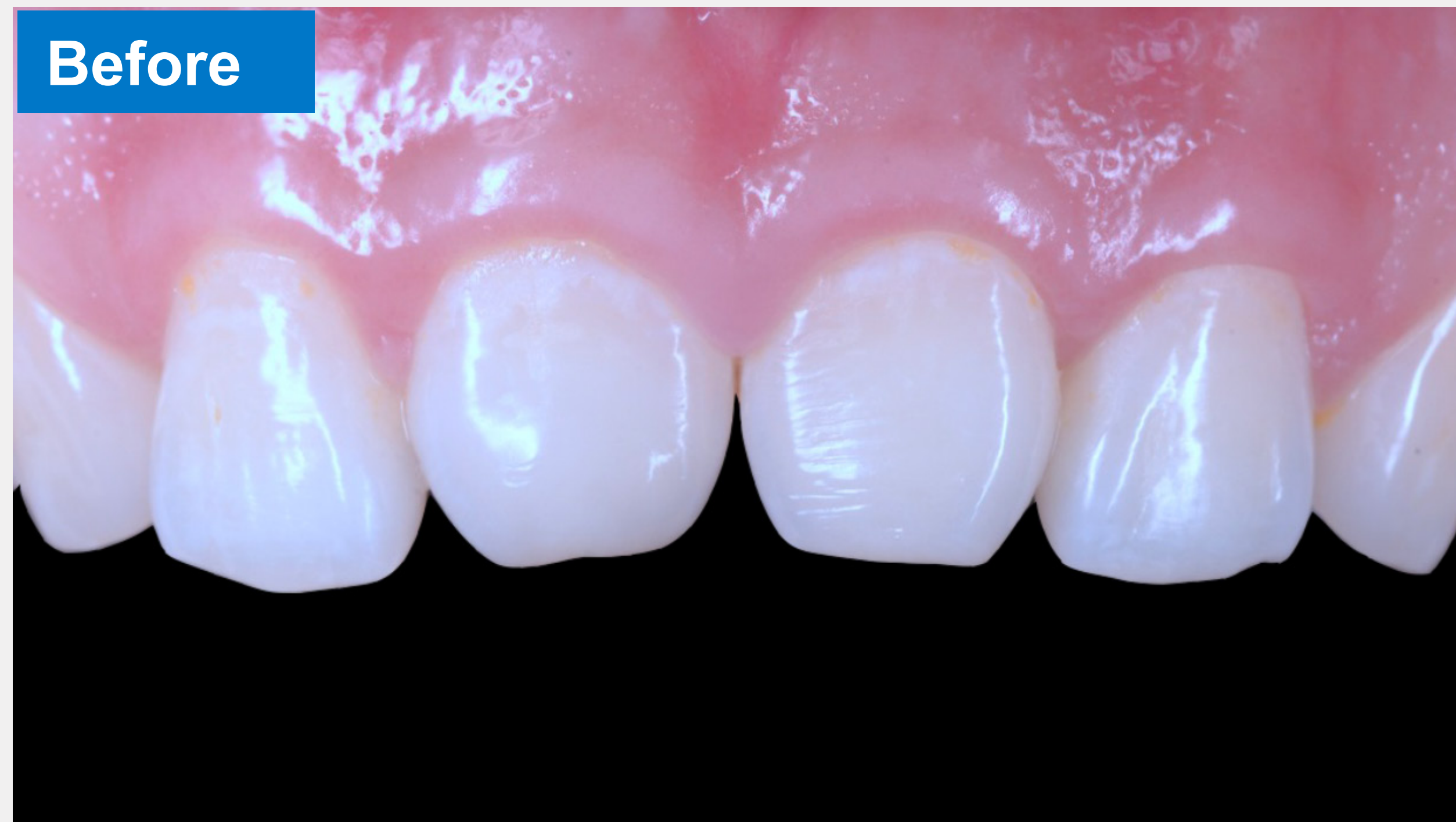

**Student:**  
Yuze Yang  
**Tutor:**  
Ling Chen  
**University:**  
Fujian Medical University  
**Country:**  
China

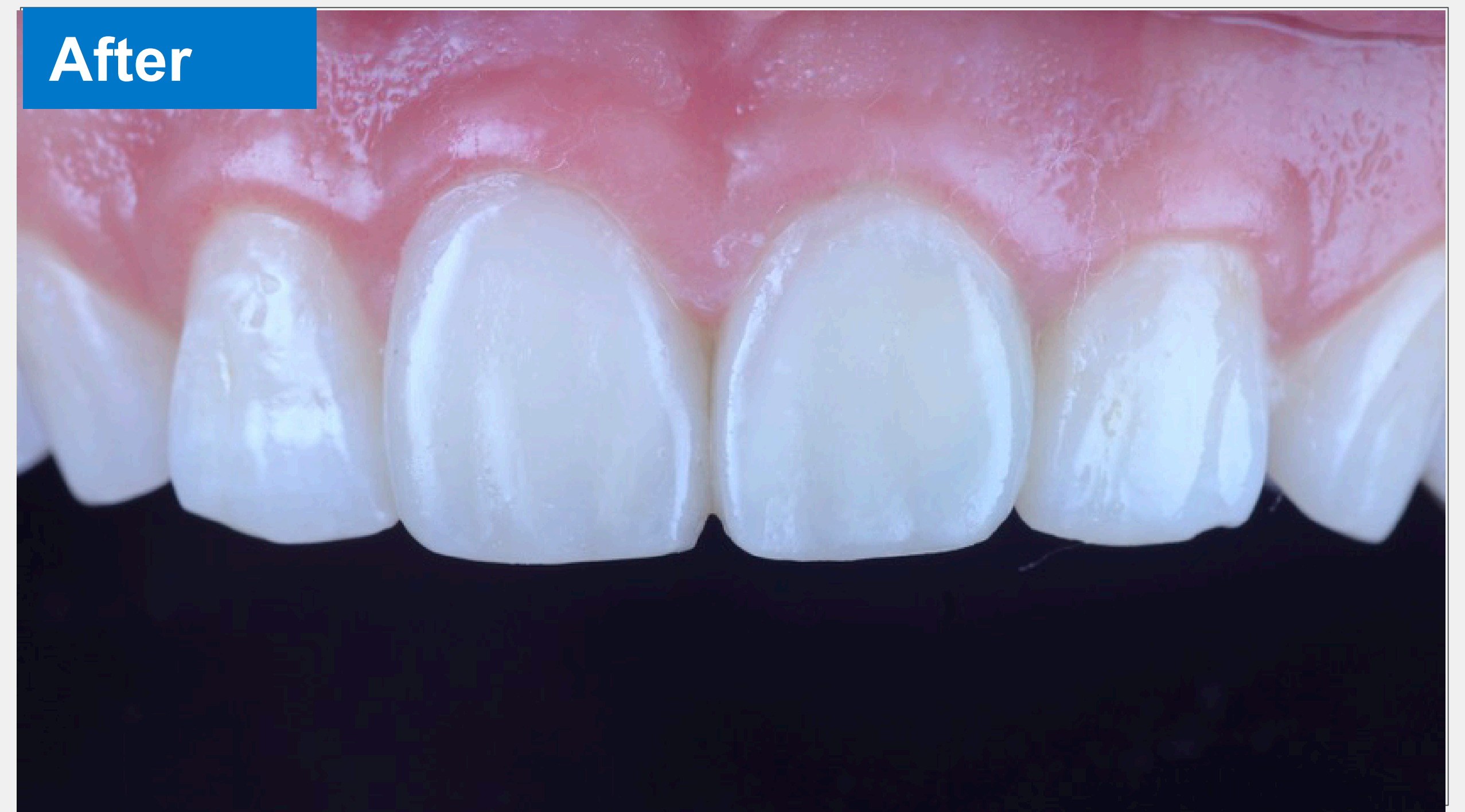

## Introduction to the case

A 24-year-old female patient came to the hospital complaining of the poor appearance of her anterior teeth. After careful examination, we found that her maxillary central incisors were too small. We intended to use digital technology for aesthetic design, and direct composite restoration was chosen to restore the tooth shape. Finally, an excellent aesthetic therapeutic effect was achieved.

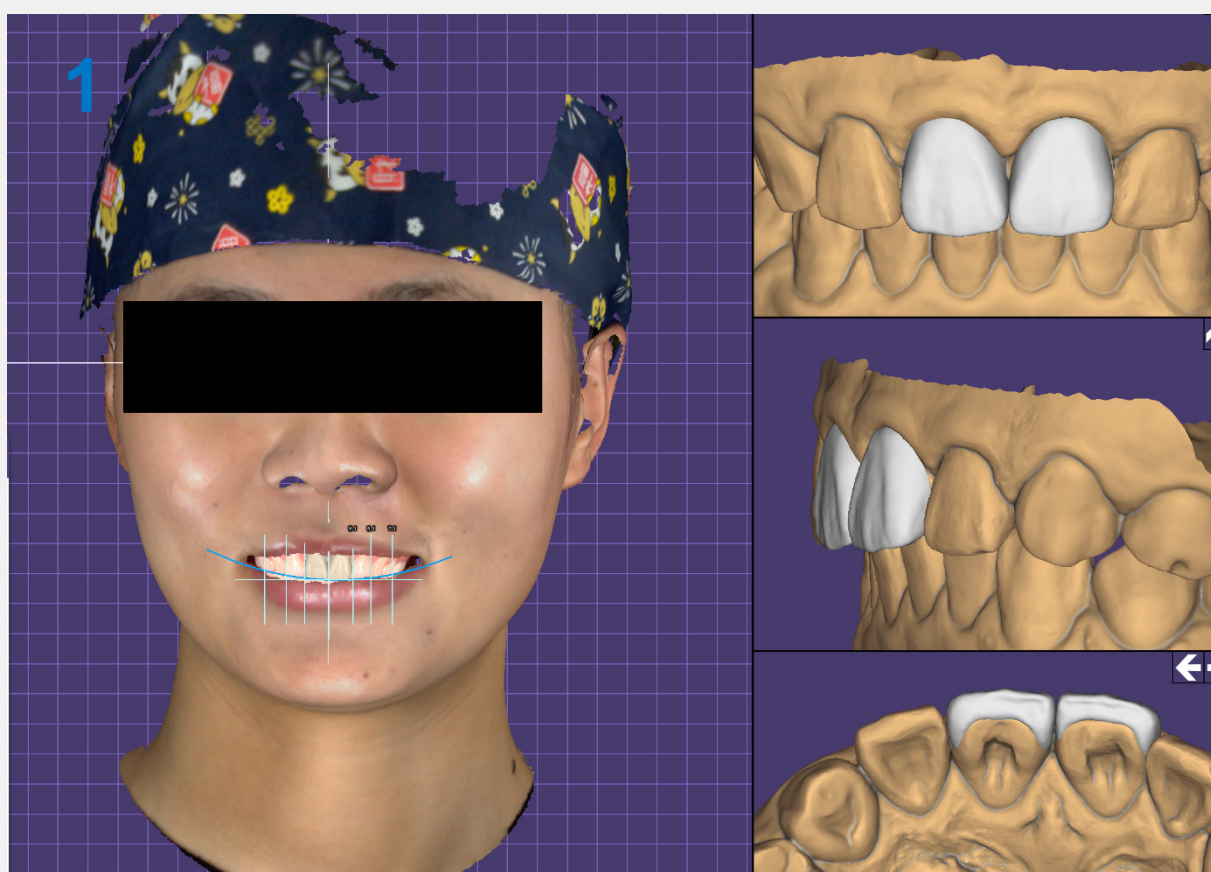


Pre-operative facial view of the restored teeth showed poor morphology of 11.21, smaller than normal teeth, resulting in poor appearance of anterior teeth.



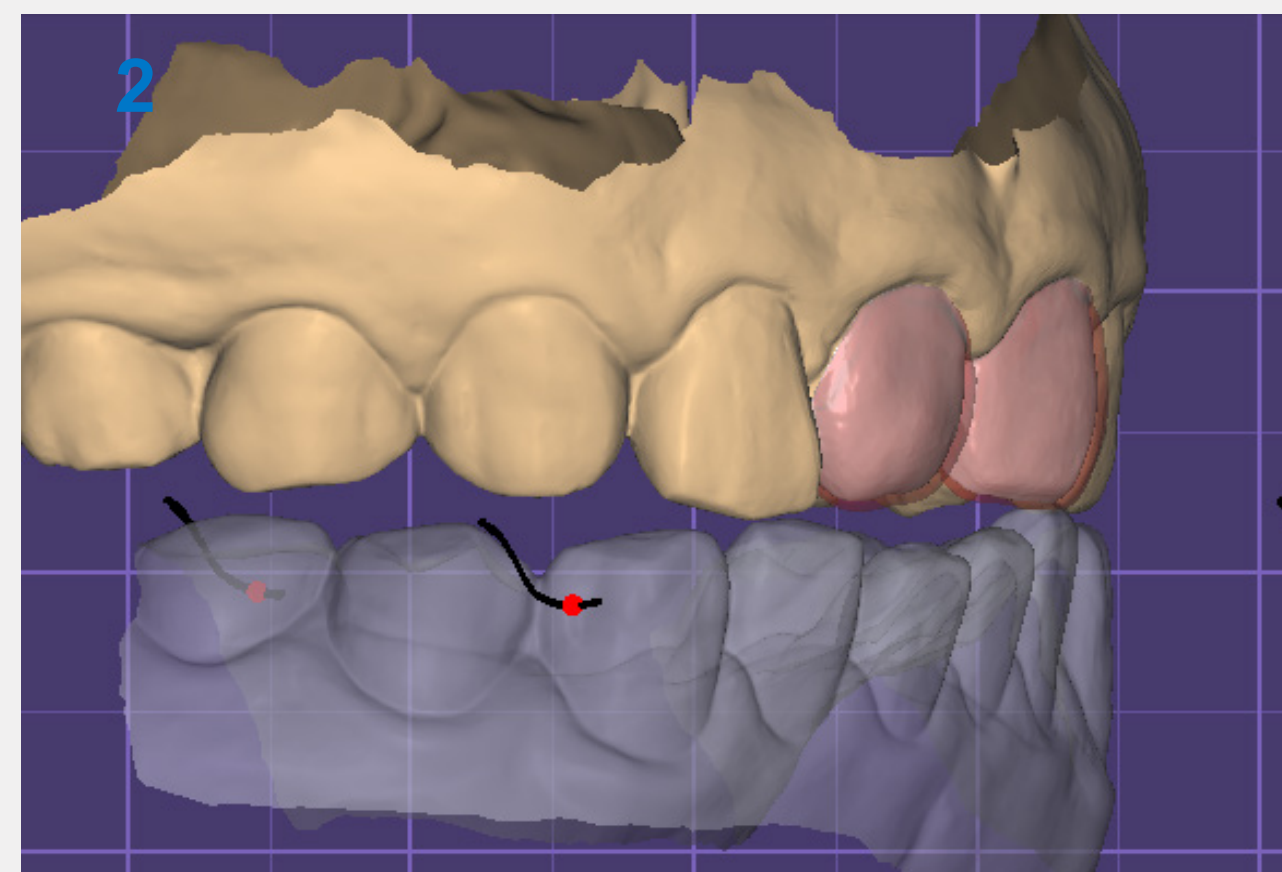
Postoperative facial view of the restored teeth. The 11.21 have been repaired with a resin veneer. The shape, color, and surface texture of the teeth met aesthetic expectations.

## Treatment steps



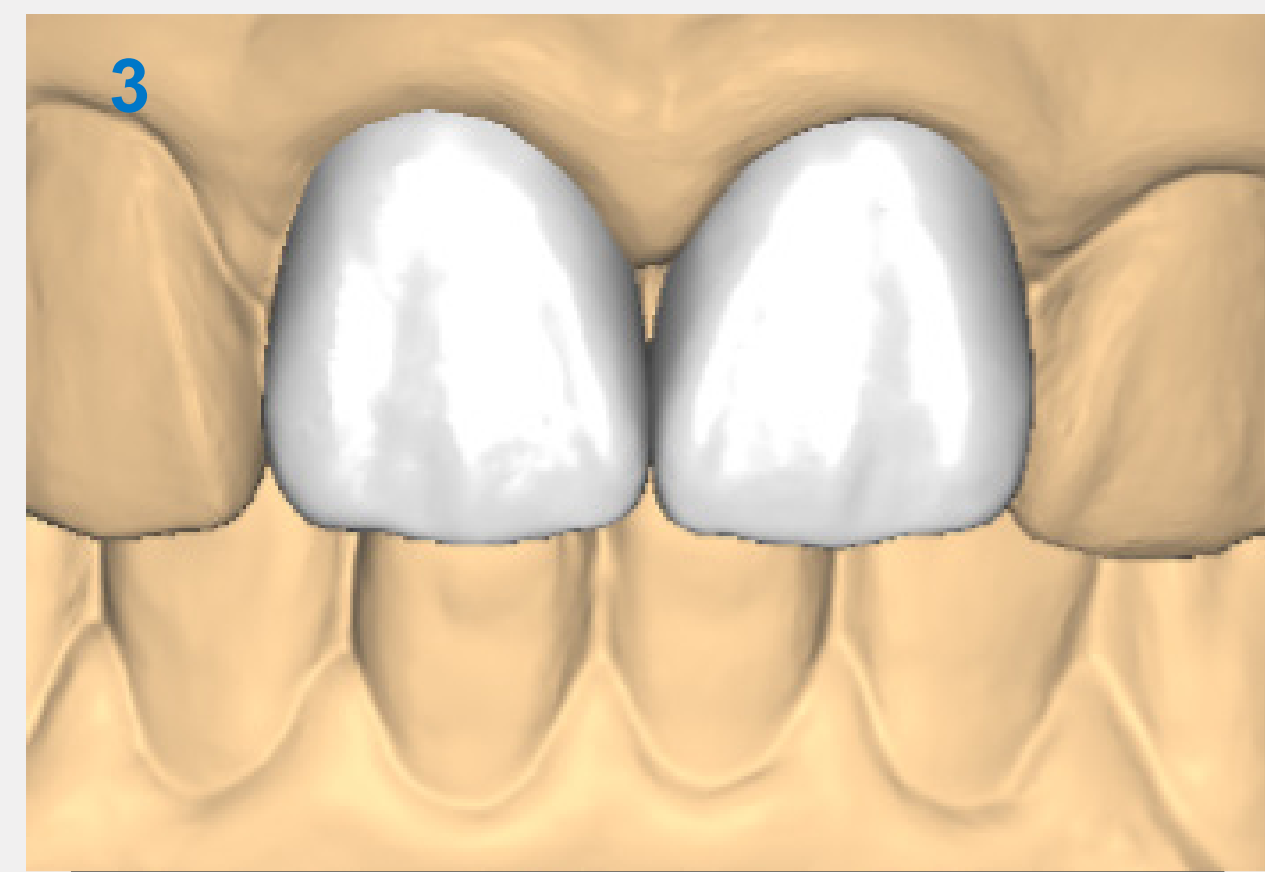
Step 1

Combining facial scanning data and intraoral scanning data, smile aesthetic analysis and teeth shape design were carried out in three-dimensional space.



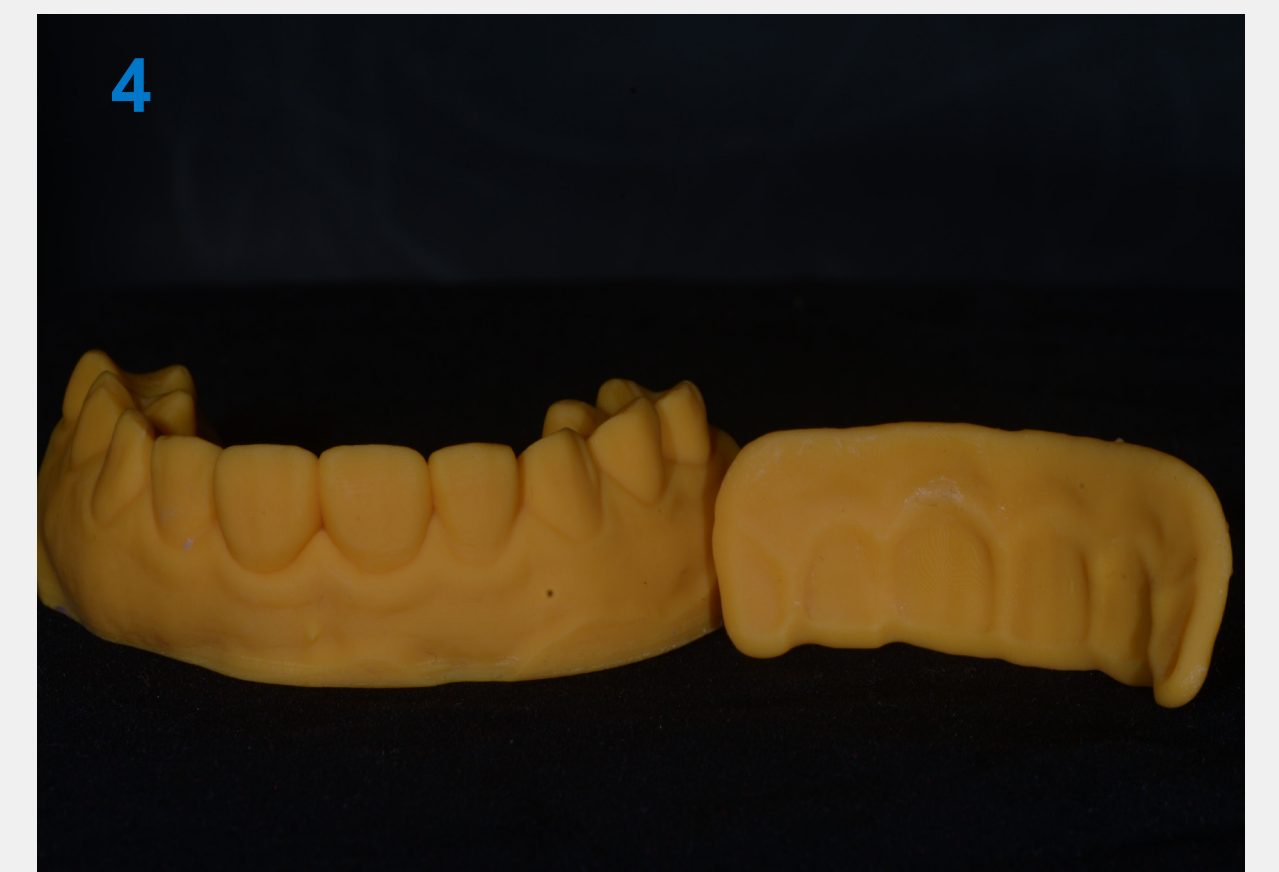Step 2

The mandibular motions data was transferred through the virtual facebow, and the occlusion on the digital restoration was accurately adjusted in dental CAD software (EXOCAD).



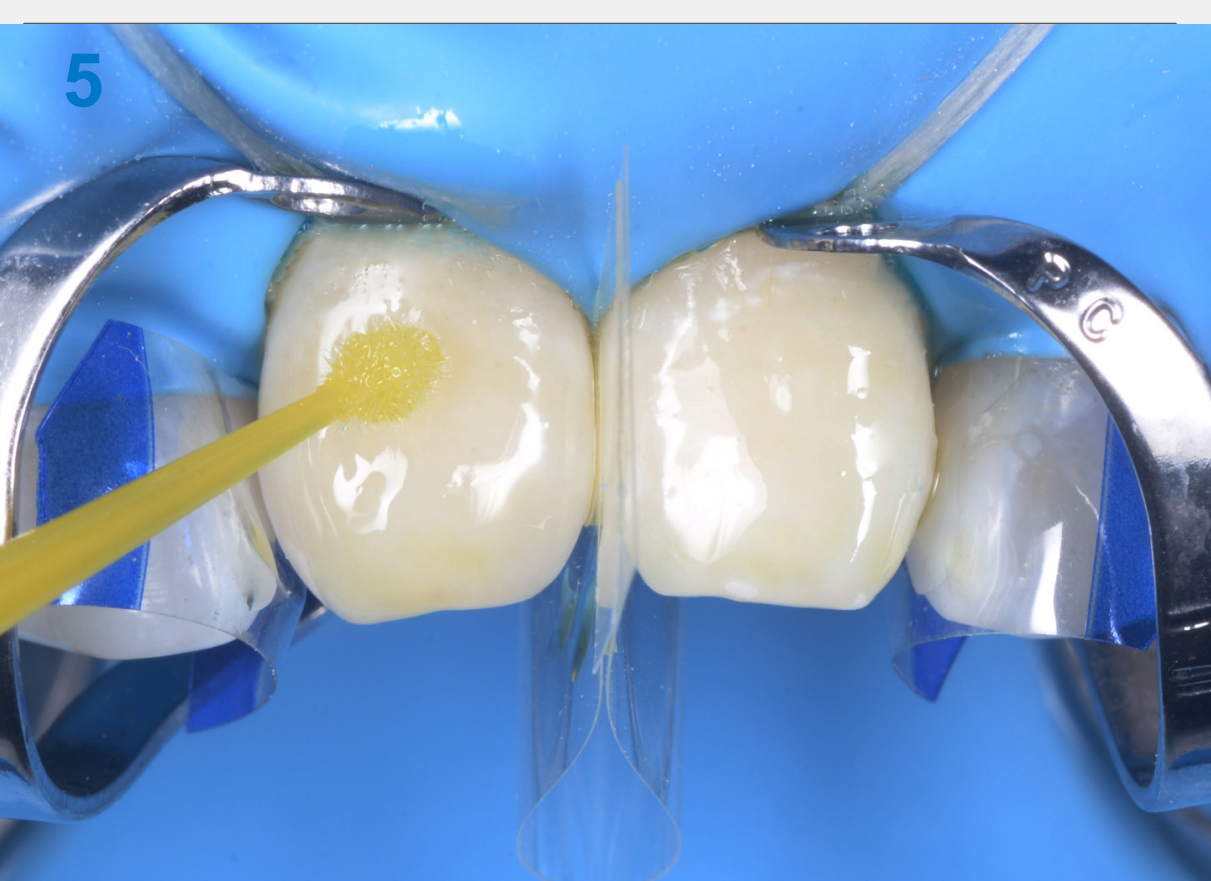Step 3

A digital diagnostic waxing of composite resin veneers was generated.



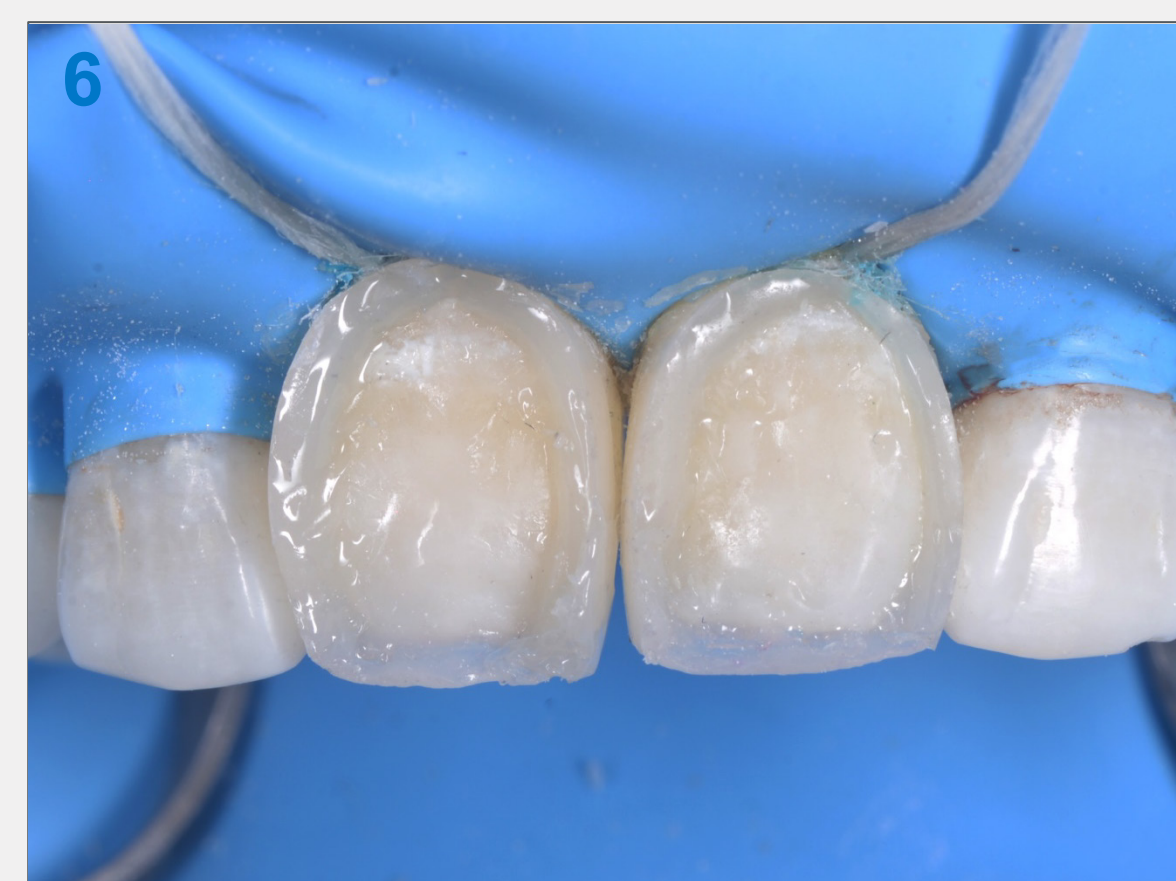Step 4

The diagnostic model and labial backplate were printed in 3D. A silicone rubber plate for palatal shaping was also made based on 3D printed replicas.



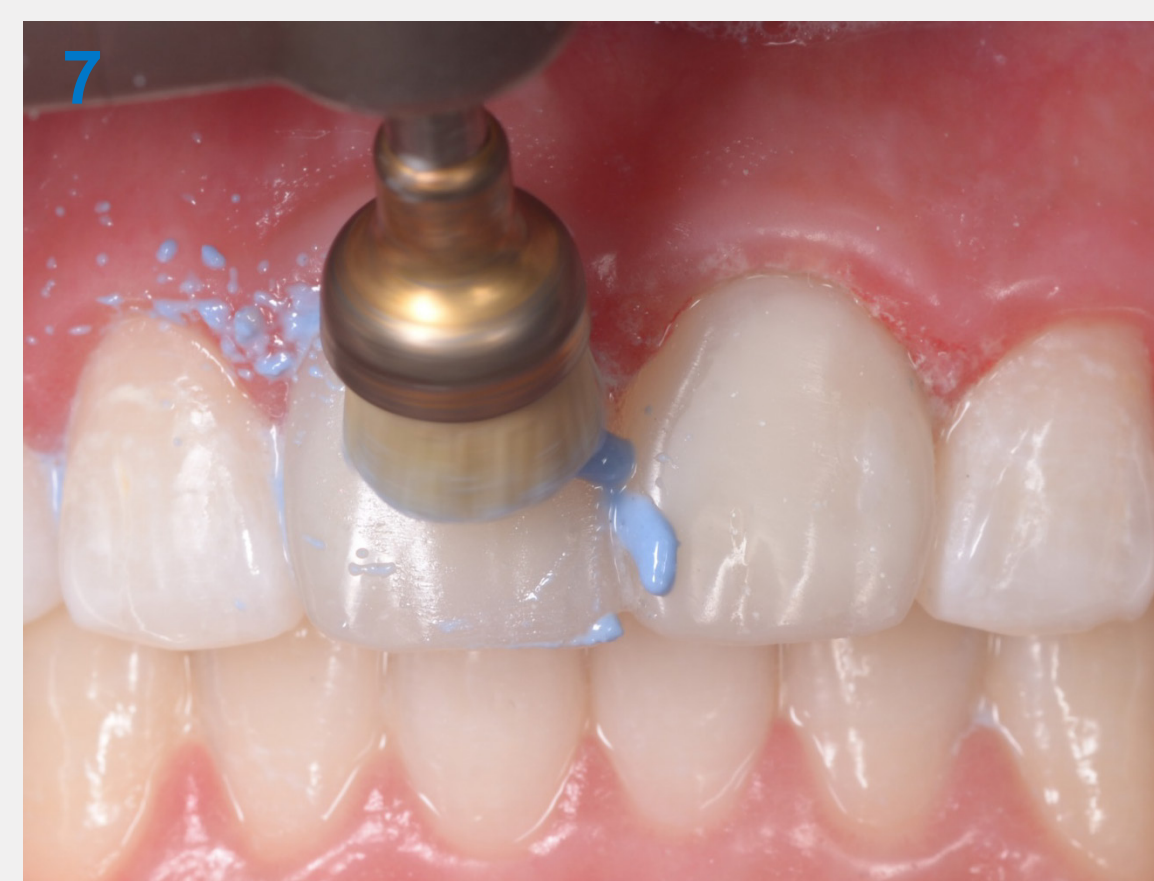Step 5

Placing the rubber dam, the teeth surfaces of 1.1 and 2.1 were treated by sandblasting to obtain roughness. Fully exposing the edge of teeth, the incisors were etched, rinsed, and dried. Apply Xeno® V+ self-etching on the etched enamels.



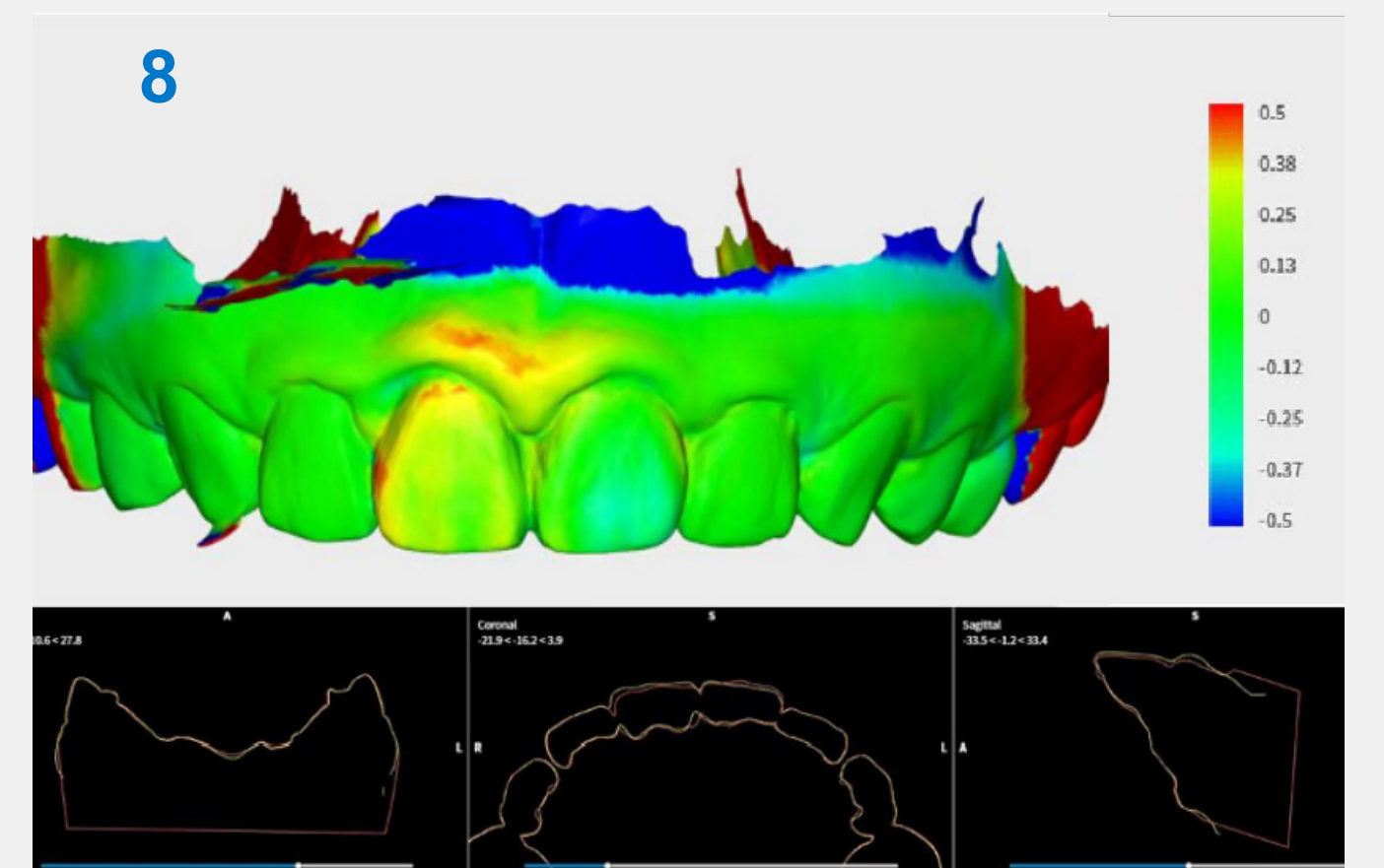
Step 6

Under the guidance of silicone rubber backplate and Palodent®V3 matrix, Dentsply ceram.xduo®(E2) was used to stack the lingual and incisal surfaces. And with the help of the labial backplate, the dentine core was built by Dentsply ceram.xduo®(D1) layer by layer until finishing the labial resin molding.



Step 7

After modifying the shape of the teeth, the teeth and restorations were shaped and polished by the Enhanced Finishing System.



Step 8

After treatment, intraoral scanning was performed again, and the data was compared and matched with the preoperative design. The final treatment effect was highly matched with the design.

## Material and Method

Intraoral scans combined with facial scans made digital smiles design more reality. With the virtual facebow transferring the mandibular motions data, the occlusion on the digital restoration could be accurate adjustment. A silicone rubber plate and Palodent®V3 matrix were used for palatal and proximal walls anatomy restoration. The Xeno® V+ self-etching offered effective and sufficient bonding. The combination of cream. x duo E1 and D2 contributed to the esthetic restoration. And final the restorations were shaped and polished by the Enhance® finishing system.

## Discussion and Conclusion

In this case, esthetic composite resin restoration combined with intraoral scanning, facial scanning, the virtual facebow, CAD, and 3D printing technology were used to restore the shape of the minor teeth. With the help of digital technology, the shape of the composite resin restorations can be best designed, making the aesthetic effect more intuitive and predictable, which is conducive to communication between doctors and patients. Due to the shade evaluation before treatment and the properties of composite resin, the color matching between the composite resin restorations and dentition can be realized. Therefore, we concluded that the combination of digital technology and resin direct restoration can achieve a better aesthetic treatment effect.